

Nerve Biopsy Techniques in Hansen's Disease

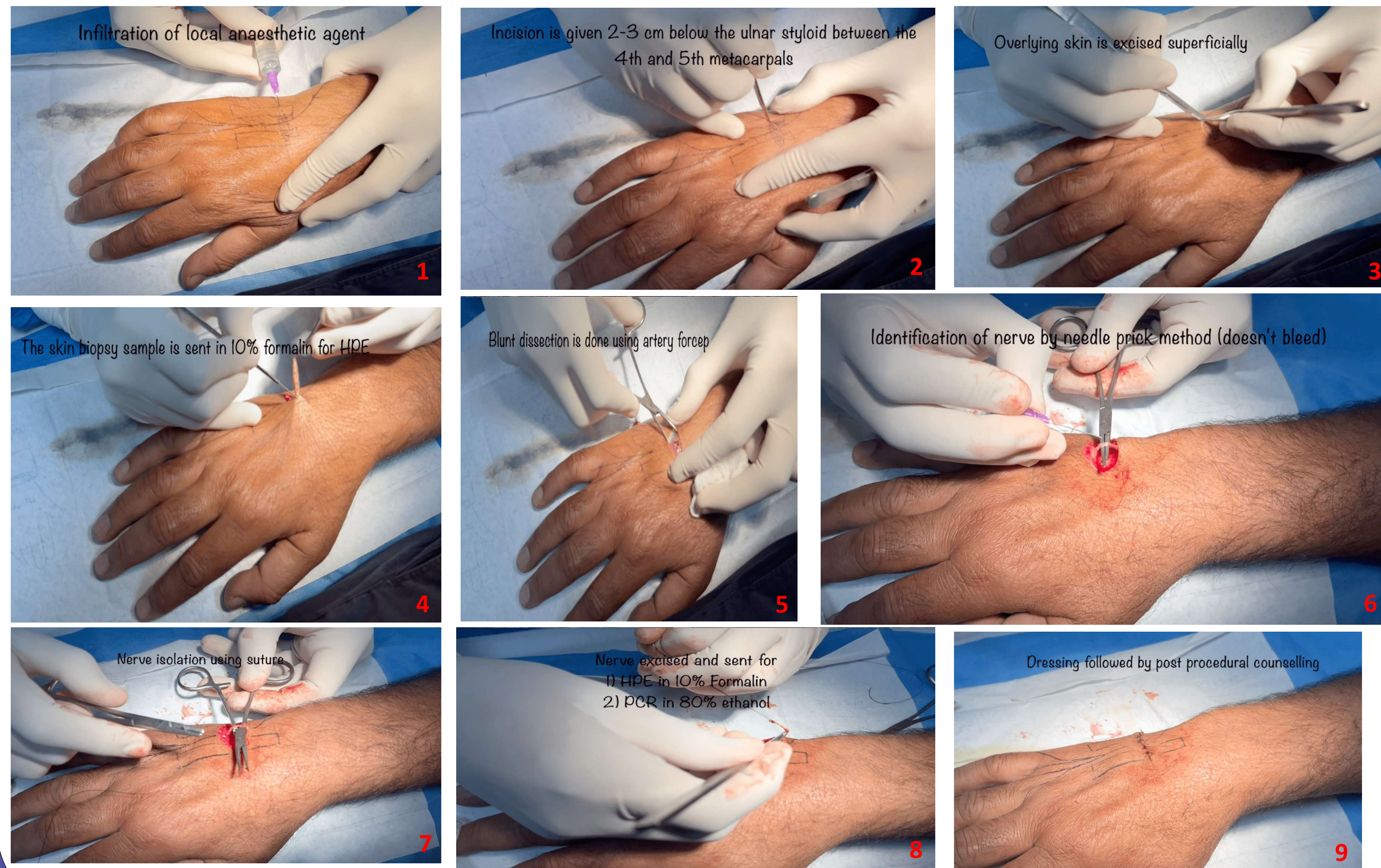Dr Sampoorna Raj Choudhary, Dr Anuj Bhatnagar, Dr Pankaj Das, Dr Lekshmi Priya

AFMC Pune

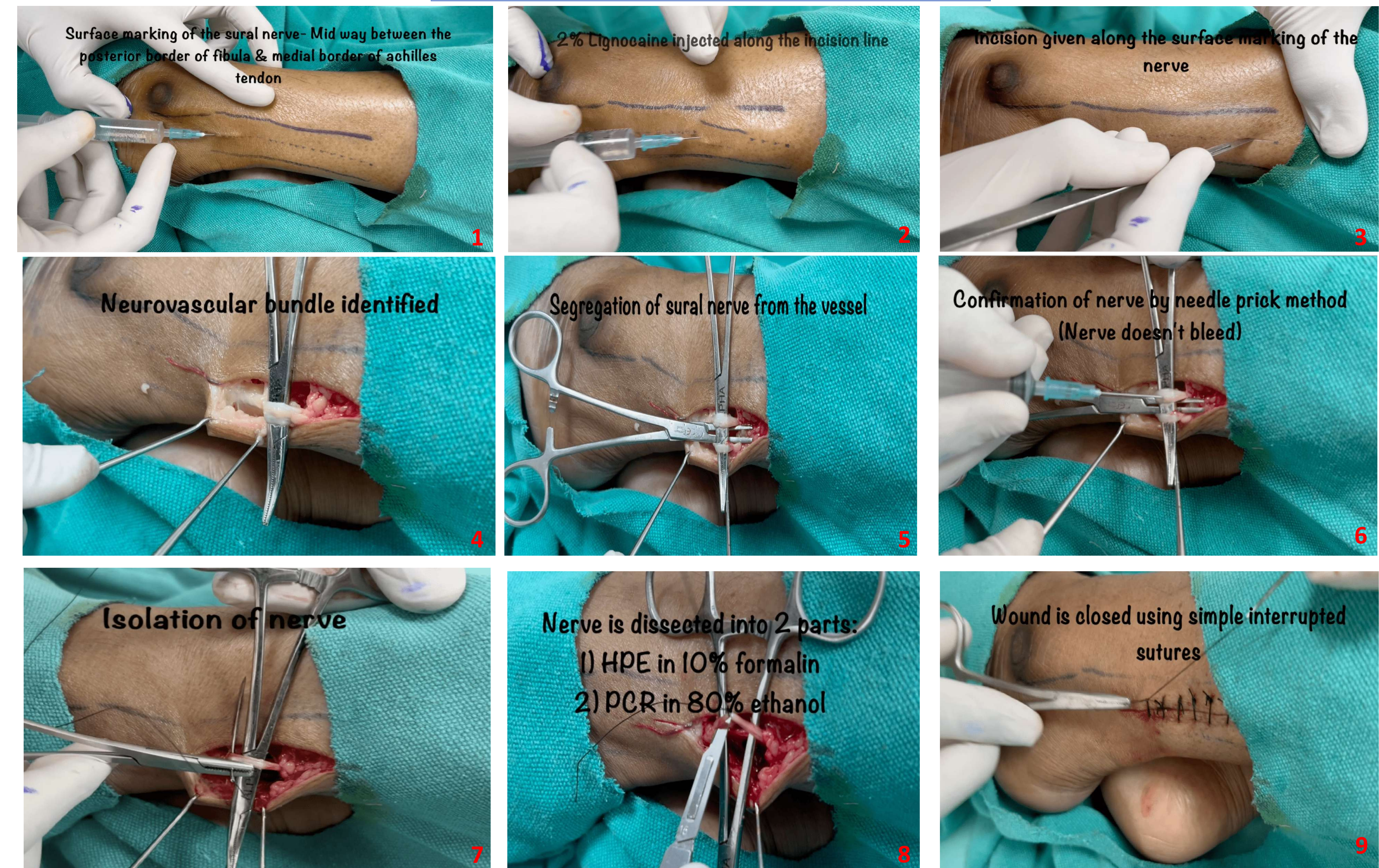
Introduction

- Pure neuritic Hansen's disease poses a significant diagnostic challenge.
- The sural and ulnar cutaneous nerves are sensory nerves that are easily accessible for biopsy.
- Correct technique and proper sampling are essential for obtaining an adequate diagnostic yield

Ulnar Cutaneous Nerve



Sural Nerve



Conclusion

- Nerve biopsy provides critical histopathological confirmation in challenging cases.
- Detailed anatomical knowledge and imaging guidance enhance safety and accuracy

Reference

Kulshreshtha D, Malhotra KP, Malhotra HS, Thacker AK, Garg RK, Singh AK, Maurya PK. Mandating nerve biopsy: A step towards personalizing therapy in pure neuritic leprosy. Journal of the Peripheral Nervous System. 2018 Sep;23(3):190-6.